# Collaborative Multidisciplinary Care Enabling End Of Life Care for a patient with MND in residential Aged Care

Donna Berry MND CNC
Calvary Kogarah Motor Neuron Service, Sydney NSW

KEYWORDS
Multidisciplinary Collaboration
Motor Neuron Disease (MND)
End of Life Care

## EXECUTIVE SUMMARY (100 words maximum)

The case study describes the collaborative multidisciplinary care supporting end of life care for a person living with advanced Motor Neuron Disease (MND) in a residential aged care facility. Managing complex physical, communication and psychosocial needs that required coordinated input from Geriatric Flying Squad, Palliative care Transitional Nurse Practitioner, MND CNC, Community Palliative Care Specialist and Aged Care Staff, family.

Through shared decision making, timely communication and clearly defined roles, the team enabled care that respected the patients' goals and priorities while maintaining comfort and dignity.

The case highlights the critical role of cross sector collaboration in delivering person centred end of life care for people with MND in aged care settings.

## INTRODUCTION

Motor Neurone Disease (MND) is a progressive, life-limiting neurodegenerative condition characterised by increasing physical disability, communication impairment, and complex symptom burden. As the disease advances, people with MND often require high levels of coordinated care across multiple services to support comfort, dignity, and quality of life. When individuals with advanced MND reside in residential aged care facilities (RACFs), the challenges of providing timely, responsive, and person-centred end-of-life care are magnified due to the involvement of multiple providers operating across health and aged care sectors.

This case study describes the multidisciplinary and cross-sector collaboration required to support end-of-life care for a person living with advanced MND in an RACF. It demonstrates how shared planning, clear communication, and defined clinical roles enabled care aligned with the patient's goals and priorities, while supporting family and staff during a complex and emotionally demanding period.

## YEAR CASE STUDY WAS IMPLEMENTED

2019__ to 2025__

CASE STUDY DETAIL

Mrs L was an older woman with a complex neurodegenerative condition whose care journey demonstrates the importance of coordinated community palliative care in the context of diagnostic uncertainty, functional decline, and end-of-life care in the residential aged care setting.

Mrs L was initially diagnosed in October 2018 with motor neurone disease (MND) Parkinsonism. After review by a senior neurologist, her diagnosis was revised to Primary Lateral Sclerosis (PLS), a slowly progressive form of MND. She was referred to the MND Service in March 2019. At this time, Mrs L was a widow living independently, though she had begun to experience increasing mobility issues. She had four supportive adult children and was in the process of moving into a retirement village to maintain independence while accessing informal support.

In July 2019, Mrs L sought a further neurological opinion and was diagnosed with an undifferentiated neurodegenerative condition, possibly corticobasal degeneration. As a result of this diagnostic change, she was discharged from the MND Service. Despite the uncertainty surrounding her diagnosis, Mrs L continued to live independently within the retirement village environment.

In April 2023, Mrs L was referred back to the MND Service following further neurological review and was re-diagnosed with PLS with an overlap syndrome. This re-engagement enabled renewed multidisciplinary input. In October 2023, as her functional status declined, she relocated to a smaller unit within the retirement village. Despite progressive disease, she remained motivated and continued attending the gym regularly, reflecting her strong desire to maintain function and quality of life.

In October 2024, Mrs L experienced a choking event while at the gym and was admitted to the Palliative Care Unit. This incident represented a clear deterioration in her condition. In November 2024, she transitioned to a Residential Aged Care Facility (RACF), where she continued to be followed up by the MND team with a focus on symptom management and anticipatory care planning.

In November 2025, Mrs L sustained an unwitnessed fall at the RACF, resulting in a head strike and haematoma below her left eye. She was transferred to a local hospital and returned to the RACF later the same day. Over the following days, both family and RACF staff noted a decline in her condition. The Geriatric Flying Squad was contacted and attended over three consecutive days, administering intravenous ceftriaxone, escalating her regular opioid from twice daily to three times daily, ceasing regular oral medications, and transitioning to subcutaneous medications. Supplemental oxygen was commenced due to increasing respiratory compromise.

With ongoing deterioration, Mrs L was referred to the Community Palliative Care Team in late November 2025. As the MND Clinical Nurse Consultant was unavailable at the time, a Transitional Nurse Practitioner attended to provide assessment and support. On 10 November 2025, Mrs L was admitted to the Hospital in the Home (HITH) pathway, and a syringe driver was commenced to manage escalating symptoms and promote comfort.

On 11 November 2025, telephone contact was made with one of Mrs L's daughters, who expressed concerns that her mother remained uncomfortable and requested a review of medications. Consultation with the RACF registered nurse confirmed ongoing distress. The Community Palliative Care Specialist reviewed Mrs L and adjusted the syringe driver accordingly. Overnight, on 12 November 2025, Mrs L died peacefully at the RACF.

Following her death, the family expressed their gratitude for the care provided during Mrs L's final days. They acknowledged the support of the MND Clinical Nurse Consultant, Community Palliative Care Medical Officer, Nurse Practitioner, and on-call nursing staff, noting that the coordinated and compassionate approach ensured Mrs L's comfort and dignity at the end of life.

This case highlights the value of integrated palliative care for people with progressive neurodegenerative disease, particularly when diagnoses evolve over time. Timely community palliative care involvement facilitated symptom control, supported family decision-making, and enabled Mrs L to remain in her familiar care environment during her final days.

**OTHER IMPORTANT NOTES FOR PREPARING YOUR CASE STUDY – DELETE THIS HEADING AND EVERYTHING BELOW BEFORE SUBMITTING YOUR CASE STUDY**

**Page Limit**

**Maximum 2 pages** of text followed by a maximum of 3 pages of supporting tables and graphics.

**Page Size and Layout**

The paper should be prepared for A4 size paper (210 x 297mm), with overall margins of 20mm on all sides of the paper (top, bottom, right and left). Use font type Arial for the entire document. Justify text.

*Do not* include page numbers, headers or footnotes.

**Abstract Title and Affiliations**

The top section of the first page of the paper should contain the case study title, author list, and affiliations.

Titles must be in 12-point font, bold and capitalised. Do not use more than two lines for the title,and try to limit the title to ten words.

Authors and affiliations must be in 10-point font. Authors with more than one affiliation should indicate additional affiliations by numbers, superscripted following the author's name.

Affiliations must be entered as follows: Organisation, City/ Town, State (abbreviated), Country

(e.g. Palliative Care NSW, Sydney, NSW, Australia)

**References**

Do not include references or acknowledgements in this abstract. If the abstract is accepted for presentation, references can be included in the final paper if you choose to submit one.

**Figures and Tables**

Figures and tables, both of which must have numbers and captions, can be included in a maximum of 3 pages at the end of the abstract. Colour images are welcome. Refer to page 3 for examples.

**Submission Instructions**

1. Maximum 2 pages of text followed by a maximum of 3 pages of supporting tables and graphics.
2. Ensure you run a spell-check and ask a peer to proof your case study prior to submitting.
3. **Convert this document to PDF format before submitting.**
4. Files larger than 10MB should be compressed as they are too large to upload.
5. Upload your abstract through the conference website: www.pcnswstateconference.org.au
   (Call for Papers section)
6. If your case study does not meet the submission requirements, it will not be processed for review.

Figure 1 is an example of a graph in the text with a caption below the figure. Please include a blank line above the figure and below the caption. The caption should be in italics.

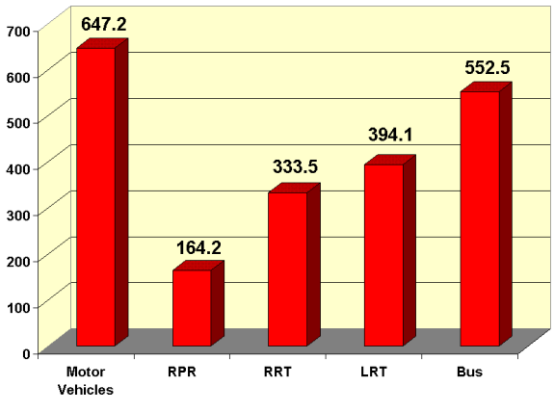


*Figure 1: Example of a Figure*

Table 1 shows an example of a table, where the caption should be on the top of the table.

*Table 1: Example of a Table*

| Heading 1 | Heading 2 | Heading 3 |
|---|---|---|
| Entry 1 | Entry 2 | Entry 3 |

Figure 2 is an example of an oversized figure.

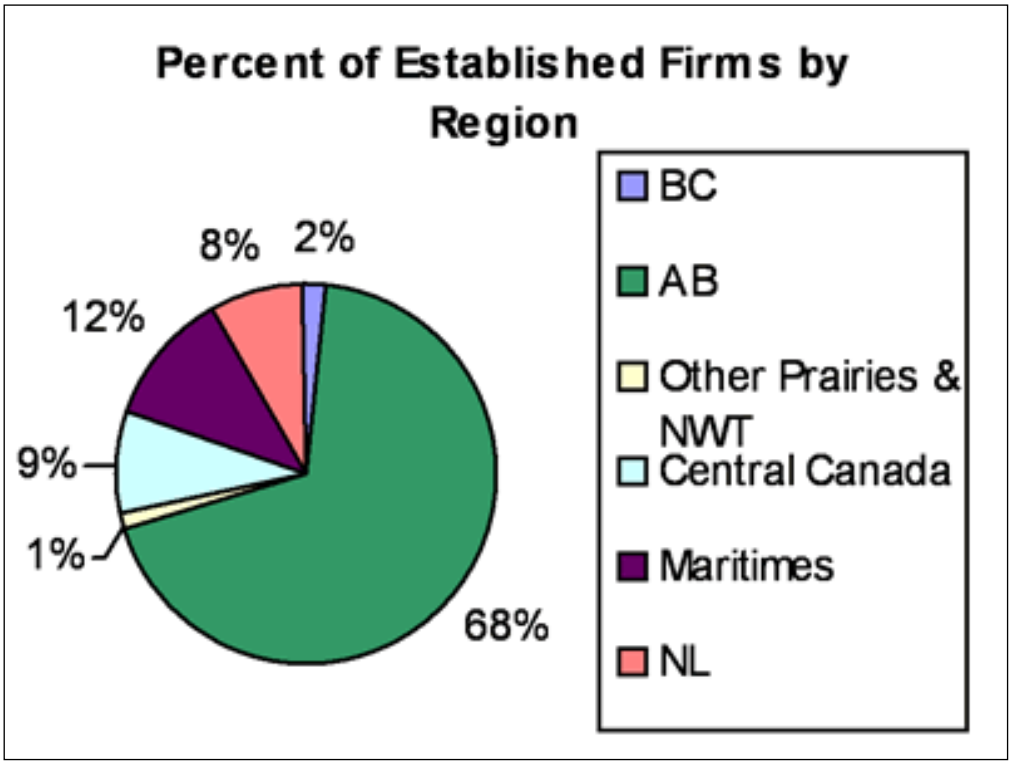


*Figure 2: Example of an Oversized Figure*